

Technical Note

Arthroscopic-Assisted Core Decompression of the Humeral Head

Joshua S. Dines, M.D., Eric J. Strauss, M.D., Stephen Fealy, M.D.,
and Edward V. Craig, M.D.

Abstract: Humeral head osteonecrosis is a progressive disease that requires prompt diagnosis and treatment. Core decompression is a viable treatment option for early-stage cases. Most surgeons perform core decompression by arthroscopically visualizing the necrotic area of bone and using a cannulated drill to take a core. Several attempts are frequently needed to reach the proper location. In the hip multiple passes are associated with complications. We describe the use of an anterior cruciate ligament (ACL) tibial drill guide to precisely localize the area of necrotic bone. Diagnostic arthroscopy is performed to assess the areas of osteonecrosis. Core decompression is performed by use of an ACL tibial guide, brought in through the anterior or posterior portal to precisely localize the necrotic area in preparation for drilling. Under image intensification, Steinmann pins are advanced into the area of osteonecrosis. Once positioned, several 4-mm cores are made. We treated 3 patients with this technique, and all had immediate pain relief. The use of the ACL guide allows precise localization of the area of humeral head involvement and avoids multiple drillings into unaffected areas. Initial indications are that arthroscopic-assisted core decompression with an ACL guide is an effective alternative to previously used methods. **Key Words:** Osteonecrosis—Humerus—Arthroscopic—Core decompression.

Osteonecrosis of the humeral head is uncommon; however, its progressive course requires prompt diagnosis and treatment to avoid compromised outcomes.¹ Many causes have been implicated including corticosteroid use, trauma, hemoglobinopathies, and systemic diseases, such as systemic lupus erythematosus.² Treatment depends on the severity of disease, with options ranging from the use of pain relievers and physical therapy to shoulder arthroplasty. Although

studies are limited, core decompression of the humeral head has been shown to be a viable treatment option for early-stage cases.³⁻⁵

Currently, most surgeons perform core decompression by arthroscopically visualizing the necrotic area of bone and drilling a K-wire into the dead area. A cannulated drill is then used to take a core of bone. Several attempts are frequently needed to reach the proper location. In the hip multiple passes have been associated with complications.⁶ This report describes the use of an anterior cruciate ligament (ACL) tibial drill guide to precisely localize the area of necrotic bone during arthroscopic core decompression.

CASE REPORTS

Patient Population

Patient 1 was a 37-year-old woman with a past medical history significant for steroid-dependent asthma, hypertension, type 2 diabetes mellitus, and

From the Sports Medicine and Shoulder Service, Hospital for Special Surgery, New York, New York, U.S.A.

The authors report no conflict of interest.

Address correspondence and reprint requests to Joshua S. Dines, M.D., Hospital for Special Surgery, 535 E 70th St, New York, NY 10021. E-mail: dinesj@hss.edu

© 2007 by the Arthroscopy Association of North America

Cite this article as: Dines JS, Strauss EJ, Fealy S, Craig EV. Arthroscopic-assisted core decompression of the humeral head. Arthroscopy 2007;23:103.e1-103.e4 [doi:10.1016/j.arthro.2006.07.011].

0749-8063/07/2301-5515\$32.00/0

doi:10.1016/j.arthro.2006.07.011

obesity. She previously underwent bilateral total hip replacements for avascular necrosis. She presented with complaints of bilateral shoulder pain for a period of 1 year. The pain was worse in the right shoulder, often waking her from sleep. She had considerable pain with range of motion, with forward flexion to 160°, external rotation to 70°, and internal rotation to T7. Magnetic resonance imaging (MRI) revealed bilateral osteonecrosis of the humeral head with subchondral lucency and sclerosis. MRI also identified a partial-thickness rotator cuff tear and evidence of a labral tear.

Patient 2 was a 49-year-old woman with a past medical history of chronic renal failure and hypertension who presented with a long-standing history of left shoulder pain. Physical examination revealed painful range of motion, with forward flexion to 150°, external rotation to 80°, and internal rotation to T12. MRI identified localized osteonecrosis of the humeral head. There was no evidence of articular cartilage collapse.

Patient 3 was a 36-year-old woman with a past medical history significant for steroid-dependent asthma who presented with severe bilateral shoulder pain due to osteonecrosis. Previously, she had undergone hemiarthroplasty of her left shoulder. The pain in the right shoulder progressed over a period of 8 to 10 months and was unresponsive to range-of-motion and strengthening exercises. Physical examination revealed forward flexion to 170°, external rotation to 85°, and internal rotation to T9. Radiographs showed a small area of osteonecrosis without collapse of the humeral head. MRI did not reveal a fracture of the articular surface,

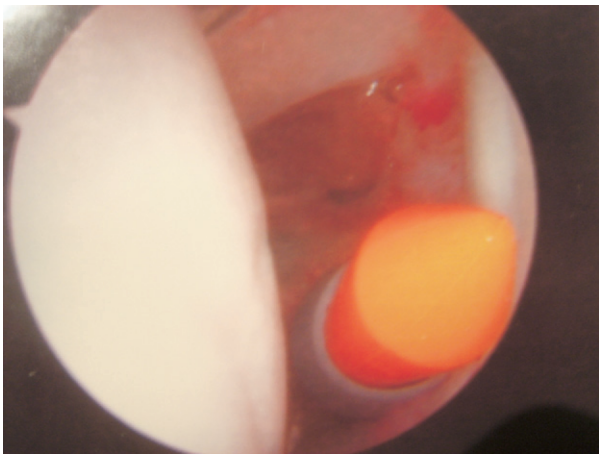


FIGURE 1. View from posterior portal showing establishment of anterior working portal and lesion of osteonecrosis affecting humeral head.

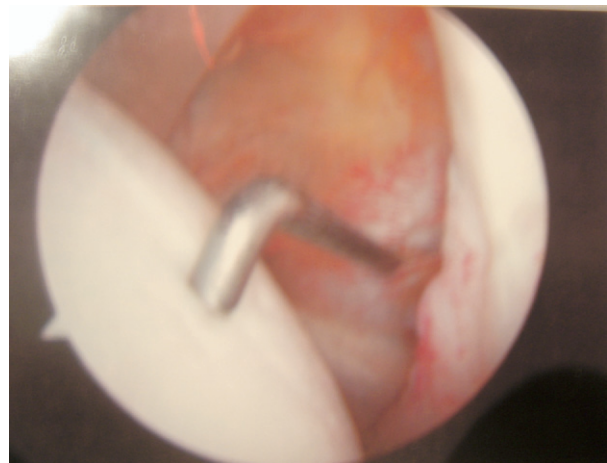


FIGURE 2. Probe exhibiting softening of humeral head consistent with area of osteonecrosis.

nor was there any appreciable deformity of the humeral head.

Surgical Technique

Each of the 3 patients underwent arthroscopic-assisted core decompression. The patients were placed in a modified beach-chair position. After routine establishment of anterior and posterior arthroscopic portals to the glenohumeral joint, diagnostic arthroscopy was performed. In all cases the humeral head was probed to assess the areas of osteonecrosis, in terms of subchondral bone support. Core decompression was performed by use of an ACL tibial guide, brought in through the anterior or posterior portal to precisely localize the necrotic area in preparation for drilling (Figs 1 and 2). By use of fluoroscopy, the area of osteonecrosis was identified, and several 3/8-in Steinmann pins were advanced, under image intensification, into the area of osteonecrosis (Figs 3 and 4). Once positioned, several 4-mm cores were made to decompress the area. The arthroscope was used to confirm that these did not penetrate into the glenohumeral joint itself. All instruments were then removed, and the portal and core decompression sites were closed with interrupted nylon sutures.

Patient Follow-Up

Patient 1, who had evidence of labral pathology on MRI, was found to have a type I SLAP lesion at the time of surgery. In addition to the core decompression, an arthroscopic debridement was performed. The patient was seen at 2 weeks, 3 months, and 7 months

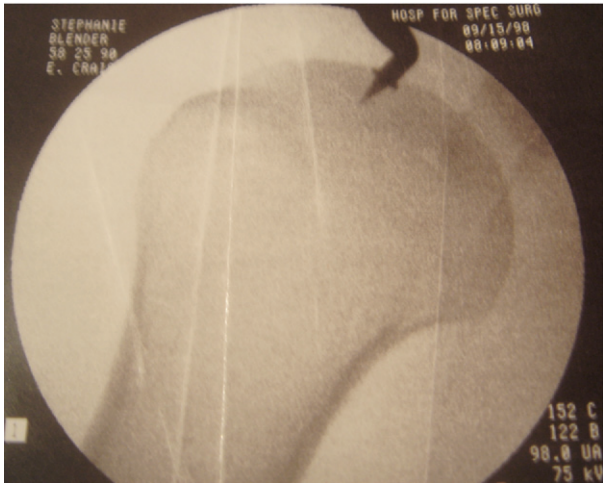

FIGURE 3. Intraoperative fluoroscopic view of ACL guide being positioned.

postoperatively. By week 2, she reported significant improvement in her right shoulder pain, and her range of motion had returned to preoperative levels. At the 3-month mark, her night pain had resolved. At the last follow-up visit, she had forward flexion to 165°, external rotation to 85°, and internal rotation to T12. She was not taking any pain medication for her shoulder.

Patient 2 was seen at 2 weeks, 8 months, and 9 months postoperatively. At the time of her first postoperative visit, she had much less pain, and her range of motion had returned to preoperative levels. Strength was 5/5 in all major muscle groups of the upper extremity. She returned 8 months after surgery because of increasing pain in the shoulder, which directly correlated with her taking Fosamax. When she stopped taking Fosamax, her pain subsided. Nine months after surgery, she complained of increasing pain in the shoulder radiating down the lateral aspect of the arm. The physical examination was notable for decreased internal rotation to T12. Under sterile conditions, an injection of Decadron and Xylocaine was administered. This significantly improved the patient's symptoms.

Patient 3 tolerated the procedure well. On follow-up by telephone at the 11-month mark, she was subjectively doing well. She was not using any pain medication for the shoulder, and she reported that her range of motion was the same as it was before surgery.

DISCUSSION

Osteonecrosis of the humeral head follows a progressive pattern, both pathologically and radiographi-

cally, similar to that observed in the femur.^{1,2} The classification system most widely used for osteonecrosis of the humeral head is a modification by Cruess⁸ of the Ficat-Arlet classification system for avascular necrosis of the hip.⁷ Stage I changes can only be detected with MRI or scintigraphy. In stage II disease the humeral head shape is maintained; however, sclerotic changes can be seen on plain radiographs, and there is evidence of bone remodeling. Stage III disease is marked by the presence of subchondral collapse or fracture, leading to a loss of humeral head architecture. Stage IV disease is characterized by the collapse of the articular surface in the affected areas. Stage V disease is evidenced by arthritic changes in the glenoid.

Treatment options are guided by the stage of disease. Stage I osteonecrosis and stage II osteonecrosis are often managed, first, by nonsurgical means, including physical therapy and analgesia. L'Insalata et al.⁵ assessed the clinical course and radiographic predictors of outcome of humeral head osteonecrosis. They found that evidence of radiographic stage III disease or greater and radiographic evidence of progression of disease were both indicative of a poor outcome. Furthermore, they found that almost three quarters of the 65 shoulders treated nonoperatively had a poor outcome. Therefore, given its success in treating osteonecrosis of the hip, core decompression has been used to treat early-stage disease of the shoulder (stages I and II).³⁻⁵ The results have been less encouraging when used after collapse (stages III and IV).^{4,5}

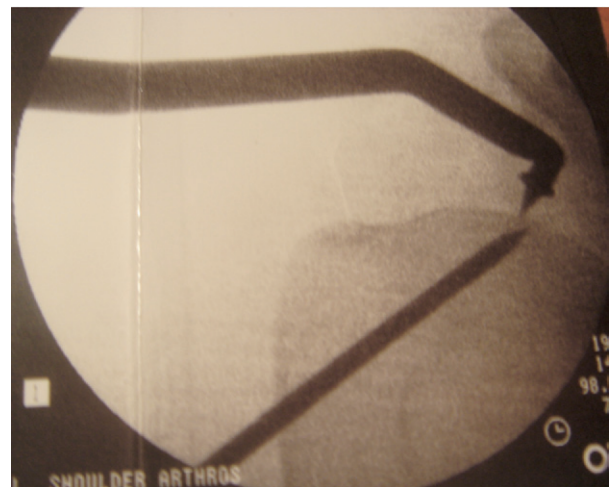


FIGURE 4. Intraoperative fluoroscopic view of Steinmann pin advancing directly toward ACL guide.

Mont et al.³ reviewed 30 shoulders treated by open core decompression with a mean follow-up of 5.6 years. Of the 14 patients with stage I or II disease, all had good or excellent results. Of the 10 patients with stage III osteonecrosis, 7 (70%) had good or excellent results. The remaining 6 patients presented with stage IV disease, and their course was not altered by core decompression. LaPorte, with Mont and colleagues, expanded the study to include 63 shoulders in 43 patients.⁴ Fifteen of 16 shoulders with stage I disease had a successful outcome, as did 15 of 17 shoulders with stage II disease. Good to excellent results were seen in 16 of 23 shoulders (70%) with stage III osteonecrosis. As had been seen in prior studies, patients with more advanced disease did poorly with core decompression. On the basis of the results, the authors concluded that core decompression is a successful tool for treating stage I, II, and III disease.

L'Insalata et al.⁵ concluded that core decompression was not effective in preventing the progression of stage III disease. This was based on their results in 5 patients with stage III disease who underwent the procedure. All shoulders exhibited evidence of clinical progression of disease despite drilling, and 4 patients required arthroplasty within 1 month to 3 years after decompression.

Johnson⁹ was the first author to describe the use of arthroscopy in patients with humeral head osteonecrosis. He performed a debridement and loose body removal. Subsequently, there have been a few case reports describing arthroscopy as a successful tool in the treatment of osteonecrosis of the humeral head.¹⁰

In our study all 3 patients underwent arthroscopic-assisted core decompression for stage II disease. Consistent with the studies detailed previously, all patients had immediate pain relief after drilling.³⁻⁵ Arthroscopy has the well-described benefits of muscular preservation, decreased recovery times, lower infection rates, and improved cosmesis and postoperative pain

when compared with open procedures. Furthermore, the use of the ACL tibial drill guide allows precise localization of the area of humeral head involvement. Ostensibly, this can help one avoid multiple drillings into unaffected areas, which is not without complications based on literature from core decompression of the hip.⁶ It can also decrease C-arm or fluoroscopy use during the procedure.

CONCLUSIONS

Although the study group was small, initial indications are that arthroscopic-assisted core decompression with an ACL tibial drill guide is an effective alternative to open core decompression.

REFERENCES

1. Cruess RL. Corticosteroid-induced osteonecrosis of the humeral head. *Orthop Clin North Am* 1985;16:789-796.
2. Lee CK, Hansen HR. Post-traumatic avascular necrosis of the humeral head in displaced proximal humerus fractures. *J Trauma* 1981;21:788-791.
3. Mont MA, Maar DC, Urquhart MW, et al. Avascular necrosis of the humeral head treated by core decompression. *J Bone Joint Surg Br* 1993;75:785-788.
4. LaPorte D, Mont MA, Maar DC, et al. Osteonecrosis of the humeral head treated by core decompression. *Clin Orthop Relat Res* 1998;355:254-260.
5. L'Insalata JC, Pagnani M, Warren RF, Dines DM. Humeral head osteonecrosis: Clinical course and radiographic predictors of outcome. *J Shoulder Elbow Surg* 1996;5:355-361.
6. Hopson CN, Silverhus SW. Ischemic necrosis of the femoral head: Treatment by core decompression. *J Bone Joint Surg Am* 1988;70:1048-1051.
7. Ficat P, Arlet J. Necrosis of the femoral head. In: Hugerford DS, ed. *Ischemia and bone necrosis*. Baltimore: Williams and Wilkins, 1980;53-75.
8. Cruess RL. Experience with steroid-induced avascular necrosis of the shoulder and etiologic considerations regarding osteonecrosis of the hip. *Clin Orthop Relat Res* 1978;86-93.
9. Johnson LL. Synovial conditions. In: *Arthroscopic surgery: Principles and practice*. St Louis: Mosby, 1986;1239-1296.
10. Hayes JM. Arthroscopic treatment of steroid induced osteonecrosis of the humeral head. *Arthroscopy* 1989;5:218-221.