

## Technical Note

# Arthroscopic Thermal Capsulorrhaphy as Treatment for the Unstable Paralytic Shoulder

Eric J. Strauss, M.D., Stephen Fealy, M.D., Michael Khazzam, M.D., Joshua S. Dines, M.D.,  
and Edward V. Craig, M.D.

---

**Abstract:** Patients who present with global capsular laxity and glenohumeral instability frequently can be treated successfully with shoulder girdle musculature strengthening exercises and activity modification. When such injury is caused by a paralytic shoulder, a rehabilitation program may not be a viable treatment option. Presented in this article are 3 patients with global capsular laxity and glenohumeral instability as a result of shoulder paralysis. We also describe an arthroscopic technique of thermal capsulorrhaphy. In our experience, arthroscopic thermal capsulorrhaphy used to treat global capsular laxity and glenohumeral instability resulting from a paralytic shoulder has decreased symptoms of shoulder instability and has significantly reduced shoulder pain. **Key Words:** Thermal capsulorrhaphy—Glenohumeral instability—Capsular laxity.

---

**G**lenohumeral stability is provided by the integrity of the surrounding soft tissue structures, the fibrocartilaginous labrum, and the rotator cuff musculature.<sup>1</sup> Any alteration in the components of this glenoid dynamic construct may result in an unstable joint articulation that produces symptoms of pain, altered range of motion, and the sensation of instability.<sup>2</sup> In 1980, Neer and Foster<sup>3</sup> first described multidirectional instability as a symptomatic glenohumeral subluxation or dislocation occurring in more than one direction.<sup>4,5</sup> The basic pathologic change leading to this condition is believed to be the development of a loose and redundant joint capsule with associated ligamentous

laxity. Etiologies of global capsular laxity and glenohumeral instability include trauma, microtrauma, congenital abnormalities, and neuromuscular disorders.<sup>1</sup> The majority of patients diagnosed with global capsular laxity and glenohumeral instability can be treated successfully with conservative methods including activity modification and shoulder girdle musculature strengthening therapy.<sup>6</sup> Burkhead and Rockwood<sup>7</sup> have reported an 80% improvement in patients' symptomatology using a regimen of rotator cuff and deltoid strengthening followed by scapular stabilizer strengthening.

For patients with global capsular laxity and glenohumeral instability resulting from brachial plexus injuries and other etiologies of the paralytic shoulder, a rehabilitation regimen is most frequently not a viable option. Currently, the treatment of the paralytic shoulder with global capsular laxity and glenohumeral instability is limited to shoulder arthrodesis and muscle transposition.<sup>8</sup> These procedures are often associated with the loss of range of motion in multiple planes if not complete loss of all glenohumeral motion as seen in an arthrodesis. Arthroscopic thermal capsulorrhaphy, a soft-tissue stabilization procedure in which

---

*From the Sports Medicine/Shoulder Service, The Hospital for Special Surgery, New York, New York, U.S.A.*

*Address correspondence and reprint requests to Edward V. Craig, M.D., Hospital for Special Surgery, 535 East 70th St, New York, NY 10021, U.S.A. E-mail: craige@hss.edu*

© 2005 by the Arthroscopy Association of North America

*Cite this article as: Strauss EJ, Fealy S, Khazzam M, Dines JS, Craig EV. Arthroscopic thermal capsulorrhaphy as treatment for the unstable paralytic shoulder. Arthroscopy 2005;21:636.e1-636.e5 [doi:10.1016/j.arthro.2005.02.011].*

0749-8063/05/2105-4239\$30.00/0

doi:10.1016/j.arthro.2005.02.011

periarticular soft tissues are heated and reduced in length by radiofrequency or laser energy to regain stability of the glenohumeral joint, has been reported with mixed results as a treatment option for global capsular laxity and glenohumeral subluxation.<sup>9</sup>

This article describes the use of arthroscopic thermal capsulorrhaphy as a potential treatment modality for patients with global capsular laxity and inferior humeral head subluxation secondary to a paralytic shoulder.

## PATIENT PROFILES

### Patient A

This patient was a 42-year-old left-hand–dominant man with a medical history of poliomyelitis, contracted at the age of 1 year, that affected mainly the right shoulder musculature. The patient presented with a 3-year history of progressive right shoulder instability, limitation of shoulder motion, and the development of a painful click with abduction, and internal and external rotation. These symptoms, especially pain, increased in intensity after a fall on his right shoulder 1 week before his initial presentation. The patient also reported frequent subluxation events of the shoulder that were precipitated by small noncontact activities. At rest, the patient's right shoulder was dislocated anteriorly and inferiorly. This could be easily reduced into the joint. Physical examination at presentation revealed complete atrophy of the deltoid, supraspinatus, infraspinatus, and pectoralis major muscles on the right side. The patient was initially treated with an arthroscopic evaluation and debridement of small tears in the anterior, posterior superior, and posterior inferior labrum, which resulted in relief of his pain and moderate improvement in his range of motion. During the arthroscopic procedure, a stretched-out and redundant rotator cuff in addition to a lax glenohumeral ligament were identified. Within 18 months of the arthroscopic debridement, symptoms of glenohumeral instability returned, with the patient complaining of pain, limitation of shoulder motion, and a persistent sensation of shoulder instability. To avoid the loss of rotation and flexibility normally associated with shoulder arthrodesis, the patient decided to undergo a soft-tissue stabilization procedure and was scheduled for arthroscopic thermal capsulorrhaphy.

### Patient B

This 33-year-old right-hand–dominant man was involved in a motorcycle accident 1 year before presentation. In the accident, he suffered multiple serious

injuries including a left clavicular fracture and an immediate flail left upper extremity. Initial electromyographic evaluation revealed a left brachial plexopathy at the level of the spinal nerves. The injury was initially treated with a left brachial plexus exploration with sural nerve grafting from the C5 nerve root to the musculocutaneous nerve. The patient presented with the complaint of severe left shoulder instability. The patient also clearly described a ptosis of the shoulder yielding easy fatigue. The patient denied any shoulder pain, but reported discomfort caused by the persistent instability. Physical examination revealed marked deltoid atrophy with no deltoid muscle contraction and inability to internally or externally rotate the shoulder. There was inferior instability and subluxation of the humerus, which showed slight but transient improvement with focused contraction of the supraspinatus muscle. After 5 months of treatment with electrical stimulation of the rotator cuff and deltoid with no improvement in the stability of the left shoulder, the patient elected to undergo arthroscopic thermal capsulorrhaphy.

### Patient C

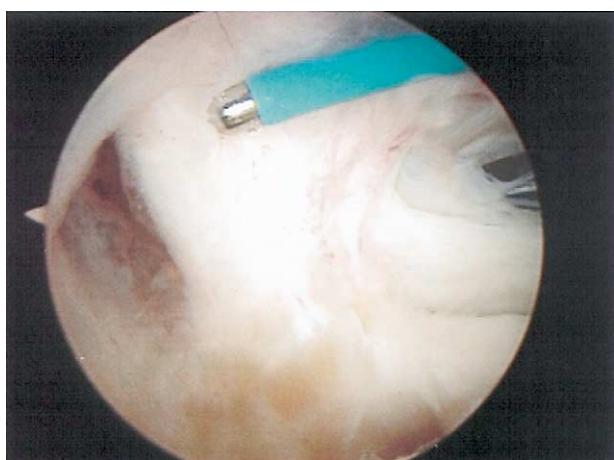This was a 65-year-old right-hand–dominant man who fell down a flight of stairs 1 month before his initial presentation. During the fall, the patient landed directly on his left shoulder, experiencing immediate pain and limitation of motion in the shoulder, neck, and upper extremity. From the time of the fall, the patient had experienced persistent weakness in the shoulder and proximal upper extremity musculature, which resulted in difficulty with arm abduction. The patient also described severe pain in the region of his left shoulder that typically worsened at night. The pain was persistent and analgesics provided only mild relief. At rest, with his arm at his side, the patient complained of a persistent inferior glenohumeral subluxation that was described as a "heavy sag." Neurologic evaluation and electromyographic studies indicated injury to the upper and middle trunks of the left brachial plexus, with associated muscle paralysis and an altered sensory examination result. Physical examination at presentation revealed extensive atrophy of the supraspinatus, infraspinatus, and deltoid in the left shoulder. The patient's range of motion consisted of passive forward flexion to 170° and external rotation to 90°, but 0° of internal rotation or abduction. There was laxity and anterior, inferior, and mild posterior translatability in addition to the presence of a 2+ sulcus sign to inferior stress. With the goals of improved left shoulder stability and pain relief, the pa-

tient was scheduled to undergo arthroscopic thermal capsulorrhaphy.

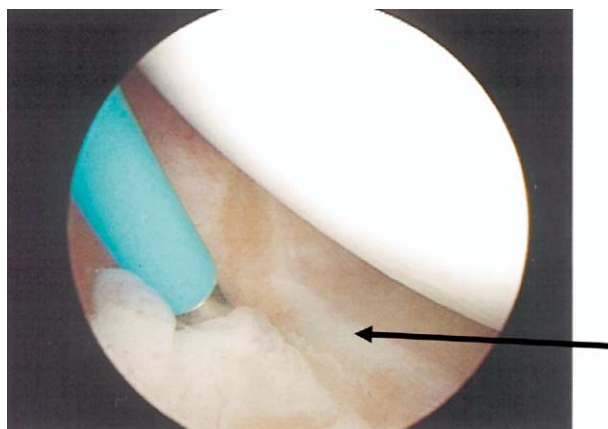
### TECHNIQUE

All 3 patients underwent arthroscopic thermal capsulorrhaphy. They were placed in the beach-chair position and prepped and draped in the usual fashion for shoulder surgery. A standard posterior portal–based arthroscopy was used with anterior superior and anterior inferior and posterior portal placement. The joint was systematically examined and then the thermal probe (Oratec Interventions, Menlo Park, CA) was brought in through the anterior superior portal. Beginning at the most posterior inferior aspect, the posterior band of the inferior glenohumeral ligament was addressed and tightened with the thermal probe. Sweeping forward, the inferior capsular pouch was systematically addressed. When the inferior capsule was completely treated, the anterior capsule was then approached. The inferior glenohumeral ligament, middle glenohumeral ligament, and the superior glenohumeral ligament were individually shrunk with the thermal probe. The arthroscope was then brought in anteriorly with the posterior portal used for probe insertion to complete the posterior thermal capsular tightening. Once again returning anteriorly, the superior rotator interval tissue was treated (Figs 1 and 2).

At the conclusion of the procedure, the humeral head appeared to be seated in the glenoid and the glenohumeral capsule was tightened from inferior to posterior and then anterior to superior, including the rotator interval. All of the instruments were then removed and the wound was copiously irrigated with



**FIGURE 1.** Shown is the thermal probe shrinking the glenohumeral capsule in the region of the rotator interval. Care must be taken to avoid the tendinous portion of the subscapularis.



**FIGURE 2.** Thermal probe used to shrink the capsule of the axillary pouch. The probe is used in a "tiger stripe" fashion (arrow) in an anterior-to-posterior direction.

antibiotic solution. The shoulder was not placed through a range of motion under anesthesia following the procedure. The arm was placed in a sling to allow further tightening of the contracted tissue. Patients were kept in a sling for a total of 6 weeks and instructed to wear the sling most hours of the day. Patients were also instructed to start shoulder-protected active and passive range of motion exercises of the elbow, neck, and hand immediately. The patients were instructed to avoid any abduction or forward flexion and external rotation past neutral for 4 weeks. Pendulum exercises were not begun immediately postoperatively as is customary following shoulder surgery. Four weeks after surgery, the patients were able to remove the sling a few times a day for passive pendulum and active assisted range of motion exercises. At 6 weeks, the sling was discontinued and motion was slowly increased to full range and strengthening exercises were continued.

### PATIENT FOLLOW-UP

All 3 patients underwent arthroscopic thermal capsulorrhaphy to treat global capsular laxity and glenohumeral instability secondary to a paralytic shoulder. Patient A was found to have a massively enlarged inferior capsular pouch both anteriorly and posteriorly with marked stretching of all the anterior and posterior glenohumeral ligaments at the time of surgery. The patient was seen 2 weeks, 3 months, and 14 months postoperatively. At all postoperative examinations, the patient reported improvement in pain and symptoms of instability. The patient began physical therapy after 6 weeks of immobilization postoperatively and presented at the 3-month follow-up with improvement of

stability and no pain. The patient was most recently seen 5 years postoperatively with no complaints of pain or gross shoulder instability. The patient did describe occasional feelings of humeral head subluxation inferiorly while sleeping.

Patient B was seen 3 weeks, 3 months, and 8 months postoperatively. At the time of his first follow-up visit, he reported subjective improvement in regard to his shoulder stability; the shoulder felt tighter and did not sag inferiorly at rest. Physical examination at 3 weeks postoperatively revealed a more satisfactory shoulder contour with an improved sulcus sign compared with his preoperative examination. Patient B began physical therapy after 6 weeks of immobilization and presented at the 3-month follow-up visit reporting no pain and a subjective 50% improvement in his shoulder stability. At month 8, patient B continued to describe improvement in the stability of his shoulder. Physical examination at that time showed external rotation to 0° and forward flexion to 95°. Over the course of the 8 months following the arthroscopic thermal capsulorrhaphy, the patient remained pain free with subjective improvement in shoulder stability and function.

Patient C was seen 2 weeks, 6 weeks, 14 months, and 15 months postoperatively. At the time of his first follow-up visit, he reported improvement with respect to his shoulder pain and instability at rest. Physical examination at that time revealed good positioning of the humeral head relative to the glenoid with no evidence of inferior subluxation. Patient C began gentle physical therapy after 4 weeks of immobilization and presented at the 6-week follow-up reporting improvement in the appearance of the inferior sulcus sign and subjective stability at rest, but described pain with an occasional click when performing sudden movements. Physical examination revealed passive forward flexion to 150°, external rotation to 70°, and improvement in inferior sag compared with the preoperative examination. At the 14-month follow-up visit, the patient described shoulder pain with occasional radiation to the neck when his arm was not supported with a sling. His shoulder remained stable with improved appearance at rest. Physical examination showed a satisfactory position of the humeral head relative to the glenoid with no increased translatability of the shoulder. Internal and external rotation in addition to inferior stress provoked pain during the examination. Under sterile conditions, a therapeutic injection with dexamethasone and lidocaine was performed. This resulted in immediate improvement in his pain symptoms, suggesting that the pain was not related to the joint but to the rotator cuff/subacromial space. One month later,

at the 15-month follow-up visit, patient C once again reported shoulder pain but graded it as less intense than the pain before the therapeutic injection. His physical examination continued to show satisfactory shoulder stability and he was started on a trial of celecoxib to treat suspected inflammatory changes in his rotator cuff.

## DISCUSSION

In the case of the paralytic shoulder, the absence of tonic and purposeful contraction of the dynamic stabilizer rotator cuff musculature places the responsibility of shoulder stability solely on the capsulolabral-ligamentous complex. Over time, the components of this static stabilizer complex may stretch, progressively increasing the size of the joint capsule and eventually stretching and enlarging the rotator cuff interval. As in other patients with global capsular laxity, these patients present with the primary complaints of shoulder pain, altered range of motion, and a subjective sensation and objective findings consistent with instability.<sup>2</sup> The inability of patients with shoulder instability secondary to a paralytic shoulder to perform routine strengthening exercises leaves the orthopaedic surgeon looking for alternative treatment options.

First introduced in 1994, thermal capsulorrhaphy as a treatment modality for shoulder instability has been used with variable results.<sup>5,6,9-12</sup> Thermal capsulorrhaphy entails applying thermal energy to periarticular soft tissues to produce tissue temperatures of 70°C to 80°C, which shrinks and thickens the tissue causing immediate joint stabilization.<sup>6,9</sup> The procedure can be performed arthroscopically through the standard anterior superior, anterior inferior, and posterior arthroscopy portals, with the patient placed in either the beach-chair or lateral decubitus position.<sup>6</sup>

A number of investigations have been performed in the attempt to understand the biologic and biomechanical effects of thermal capsulorrhaphy. It was initially theorized by Hayashi and Markel<sup>9</sup> that when collagen is heated to 60°C to 70°C, its triple helical structure unwinds and this is followed over time by the random reformation of the collagen cross-links in a new, overall shortened state.<sup>9,11</sup> This theory was refuted by a recent animal study<sup>5</sup> that showed evidence of active tissue healing and new collagen synthesis by residual fibroblasts in the heat-treated structures. The authors of this study suggest that the treated collagen acts as a framework or scaffold for new collagen matrix synthesis in a now shortened configuration.<sup>5,6</sup> This process may take 4 to 6 weeks to begin



and several more months for the changes to become mature.<sup>6</sup> One caveat that must be mentioned when examining these animal and cadaveric studies is that the majority of these investigations have been performed on normal tissue, which may not accurately reflect the response that pathologically lax periarticular soft tissues have when exposed to thermal energy.<sup>5</sup>

There have been several reports of initial success and later clinical failures using thermal capsulorrhaphy in active patients with normal neuromuscular examination results.<sup>11,12</sup> Wong et al.<sup>13</sup> surveyed 379 orthopaedic surgeons on shoulder procedures involving the use of thermal energy over a 5-year period. Of 236,015 shoulder procedures, 14,277 (6%) involved the use of thermal energy (1,077 involved laser energy, 9,013 monopolar radiofrequency, and 4,187 bipolar radiofrequency) for the treatment of glenohumeral instability. The rates of recurrent instability after laser, monopolar radiofrequency, and bipolar radiofrequency capsulorrhaphy were 8.4%, 8.3%, and 7.1%, respectively. A total of 196 patients (1.4%) (3 treated with laser energy, 133 with monopolar radiofrequency, and 60 with bipolar radiofrequency) had a postoperative axillary neuropathy; 93% of 196 had a sensory deficit only. Of these patients, 95% recovered completely, with sensory deficits lasting an average of 2.3 months and the combined deficits, an average of 4 months. There was adhesive capsulitis in 41 cases.<sup>11</sup> In a study to identify risk factors for poor outcome after thermal capsulorrhaphy, Anderson et al.<sup>11</sup> found that previous operations and multiple recurrent dislocations were associated with poor outcome at a highly significant level. Of 106 patients who underwent thermal shrinkage, 15 patients with treatment failure were identified. The average age of the 78 male and 28 female patients was 26 years (range, 15 to 52 years). All patients in the study had thermal capsulorrhaphy performed with the use of a monopolar radiofrequency probe. Postoperatively, all patients were treated according to a protocol that involved strict use of a sling immobilizer for the first 4 weeks after surgery. Of the 15 patients in the failure group, 4 had had dislocations before treatment and had redislocations after thermal capsulorrhaphy, 2 patients had recurrent subluxations, and 1 had a concurrent rotator cuff repair and reported persistent weakness. The 8 remaining patients had preoperative pain or looseness and these symptoms continued after treatment. The proposed risk factors for failure of thermal capsular shrinkage were previous surgery to the affected shoulder, multiple dislocations before surgery, contact sports participation, multidirectional instability, associated injuries (requiring

repair and excluding labral debridement), and age at presentation.<sup>12</sup>

In our study, all of the patients presented with symptomatology associated with global capsular laxity and inferior glenohumeral instability secondary to a paralytic shoulder. Two of the patients had post-traumatic brachial plexus injuries and 1 patient had shoulder girdle paralysis associated with childhood poliomyelitis infection. Each was treated with arthroscopic thermal capsulorrhaphy to remedy the loose and redundant joint capsule and pathologic laxity in the ligamentous complex and musculotendinous system. All of the patients experienced immediate improvement in the degree of shoulder stability following the thermal capsular treatment. Follow-up examinations showed improvement in glenohumeral stability both subjectively and on physical examination. Although long-term follow-up is not yet available, the use of arthroscopic thermal capsulorrhaphy for the treatment of the unstable paralytic shoulder seems to be a viable, minimally invasive alternative to shoulder arthrodesis and open soft-tissue stabilization techniques.

## REFERENCES

1. An Y, Friedman R. Conservative management of shoulder injuries. *Orthop Clin North Am* 2000;31:275-285.
2. Norris T. Diagnostic techniques for shoulder instability. *Instr Course Lect* 1985;34:239-257.
3. Neer CS, Foster CR. Inferior capsular shift for involuntary inferior and multidirectional instability of the shoulder: A preliminary report. *J Bone Joint Surg Am* 1980;62:897-908.
4. Neer C. Involuntary inferior and multidirectional instability of the shoulder: Etiology, recognition and treatment. *Instr Course Lect* 1985;34:232-238.
5. Fitzgerald B, Watson T, Lapoint J. The use of thermal capsulorrhaphy in the treatment of multidirectional instability. *J Shoulder Elbow Surg* 2002;11:108-113.
6. Giffin J, Annunziata C, Bradley J. Thermal capsulorrhaphy for instability of the shoulder: Multidirectional and posterior instabilities. *Instr Course Lect* 2001;50:23-28.
7. Burkhead W, Rockwood C. Treatment of instability of the shoulder with an exercise program. *J Bone Joint Surg Am* 1992;74:890-896.
8. Cofield R, Briggs B. Glenohumeral arthrodesis: Operative and long-term functional results. *J Bone Joint Surg Am* 1979;61:668-677.
9. Hayashi K, Markel D. Thermal capsulorrhaphy treatment of shoulder instability. *Clin Orthop* 2001;390:59-72.
10. Carson E, Warren R, Craig E. Multidirectional instability: Diagnosis and management. In: Craig E, ed. *Clinical Orthopaedics*. Baltimore: Lippincott Williams & Wilkins, 1999; 203-212.
11. Anderson K, Warren RF, Altchek DW, Craig EV, O'Brien SJ. Risk factors for early failure after thermal capsulorrhaphy. *Am J Sports Med* 2002;30:103-107.
12. Savoie F, Field L. Thermal versus suture treatment of symptomatic capsular laxity. *Clin Sports Med* 2000;19:63-75.
13. Wong KL, Williams GR. Complications of thermal capsulorrhaphy of the shoulder. *J Bone Joint Surg Am* 2001; 83(suppl):151-155.