

# Long Head of the Biceps Tendinopathy: Diagnosis and Management

Shane J. Nho, MD, MS  
Eric J. Strauss, MD  
Brett A. Lenart, MD  
CDR Matthew T. Provencher,  
MD, MC, USN  
Augustus D. Mazzocca, MD, MS  
Nikhil N. Verma, MD  
Anthony A. Romeo, MD

From the Department of Orthopaedic Surgery, Section of Shoulder and Elbow Surgery, Division of Sports Medicine, Rush University Medical Center, Chicago, IL (Dr. Nho, Dr. Strauss, Dr. Lenart, Dr. Verma, and Dr. Romeo), Department of Orthopaedic Surgery, Naval Medical Center San Diego, San Diego, CA (Dr. Provencher), and New England Musculoskeletal Institute, University of Connecticut Health Center, Farmington, CT (Dr. Mazzocca).

The views expressed in this article are those of the authors and do not reflect the official policy or position of the Department of the Navy, Department of Defense, or US Government.

*J Am Acad Orthop Surg* 2010;18:645-656

Copyright 2010 by the American Academy of Orthopaedic Surgeons.

## Abstract

Tendinopathy of the long head of the biceps brachii encompasses a spectrum of pathology ranging from inflammatory tendinitis to degenerative tendinosis. Disorders of the long head of the biceps often occur in conjunction with other shoulder pathology. A thorough patient history, physical examination, and radiographic evaluation are necessary for diagnosis. Nonsurgical management, including rest, nonsteroidal anti-inflammatory drugs, physical therapy, and injections, is attempted first in patients with mild disease. Surgical management is indicated for refractory or severe disease. In addition to simple biceps tenotomy, a variety of tenodesis techniques has been described. Open biceps tenodesis has been used historically. However, promising results have recently been reported with arthroscopic tenodesis.

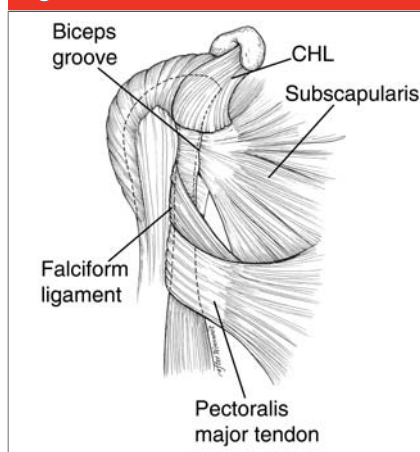
Despite considerable research into the anatomy of the long head of the biceps (LHB) brachii tendon and the pathologic conditions that affect it, controversy persists in the literature regarding the function of the LHB and the appropriate management of its disorders. Tendinopathy of the LHB has inflammatory, degenerative, overuse-related, and traumatic causes.

Tendinitis of the LHB is an inflammatory tenosynovitis that occurs as the tendon courses along its constrained path within the bicipital groove of the humerus.<sup>1,2</sup> Similar to other types of biceps tendinopathy, LHB tendinitis presents with anterior shoulder pain and is often exacerbated by overuse. Although isolated bicipital tendinitis has been described, LHB tendinitis more commonly presents in combination with other shoulder pathology, including impingement, rotator cuff disorders,

superior labrum anterior-posterior (SLAP) lesions, bursitis, and acromioclavicular joint disorders. The sheath of the LHB is an extension of the synovium of the glenohumeral joint and is closely associated with the rotator cuff; thus, inflammation of one structure can lead to the development of disease in the other.<sup>3,4</sup>

## Anatomy

The LHB originates at the supraglenoid tubercle and the superior glenoid labrum. It inserts distally, along with the short head of the biceps, onto the radial tuberosity, with an attachment to the fascia of the medial forearm via the bicipital aponeurosis. The site of the LHB origin from the glenoid labrum is variable; in most cases, it arises either mostly posterior or completely posterior (55.4% and 27.7%, respectively).<sup>5</sup> The intra-articular portion of the

**Figure 1**

Anatomic structures around the long head of the biceps. The musculotendinous junction lies just proximal to the inferior border of the pectoralis major tendon. The dashed lines delineate underlying structures. CHL = coracohumeral ligament

LHB tendon is extrasynovial, and it obliquely spans the glenohumeral joint anterosuperiorly, adjacent to the rotator interval.

The bicipital groove is an hourglass-shaped corridor between the greater and lesser tuberosities of the humeral head; this groove is narrowest and deepest at its mid portion.<sup>6</sup> Although the contours of the tuberosities help to contain the LHB tendon within the bicipital groove, most of the restraint during tendon

excursion is provided by the surrounding soft tissues. Recent clinical and anatomic studies have attempted to better define the soft-tissue contributions to biceps stability within the groove.<sup>7,8</sup> These studies have noted the importance of the subscapularis tendon, supraspinatus tendon, coracohumeral ligament (CHL), and superior glenohumeral ligament (SGHL), which together serve as a stabilizing tendoligamentous biceps sling or pulley that maintains the biceps within its groove (Figure 1).

In an anatomic study, Gleason et al<sup>7</sup> noted that superficial fibers from the subscapularis tendon continued over the biceps and inserted onto the base of the greater tuberosity. Along with lateral fibers from the supraspinatus tendon, these superficial fibers helped to form the roof of the biceps sheath. The authors also noted that deep fibers from the subscapularis tendon continued along the bottom of the bicipital groove, thereby helping to form the floor of the biceps sheath. Contributions to the biceps sling were provided by the CHL and SGHL.

The transverse humeral ligament was once believed to be of primary importance for LHB stability; however, its presence and role have been questioned.<sup>6,7</sup> Based on their dissections, Gleason et al<sup>7</sup> concluded that

no identifiable transverse humeral ligament exists. Instead, they found the roof of the biceps sheath to be formed by fibers from the subscapularis tendon, supraspinatus tendon, and CHL. Distal to the tuberosities, the pectoralis major muscle insertion appears to play a role in stabilizing the LHB. The falciform ligament, a fibrous expansion from the sternocostal head, has been shown to attach to both sides of the bicipital groove, enveloping the biceps.<sup>6,9</sup>

The LHB tendon is a primary pain generator in the anterior aspect of the shoulder, and it has been shown to receive both sensory and sympathetic innervation.<sup>10</sup> In a cadaver study, Alpantaki et al<sup>10</sup> demonstrated the presence of an asymmetrically distributed neuronal network composed of thinly myelinated and unmyelinated fibers along the course of the tendon. This innervation was shown to predominate in the proximal area of the LHB, near its origin.

The blood supply to the LHB is derived primarily from branches of the anterior circumflex humeral artery, which course along the bicipital groove.<sup>1</sup> Labral branches from the suprascapular artery also may provide blood supply, especially to the proximal portion of the biceps tendon near its origin.<sup>11</sup> However, recent studies have shown that there is

Dr. Nho or an immediate family member has received research or institutional support from Arthrex, DJ Orthopaedics, Linvatec, Smith & Nephew, Athletico, and MioMed. Dr. Provencher or an immediate family member serves as a board member, owner, officer, or committee member of the American Orthopaedic Society for Sports Medicine, Arthroscopy Association of North America, American Academy of Orthopaedic Surgeons, and Society of Military Orthopaedic Surgeons. Dr. Mazzocca or an immediate family member is a member of a speakers' bureau or has made paid presentations on behalf of, serves as a paid consultant to or is an employee of, and has received research or institutional support from Arthrex. Dr. Verma or an immediate family member is a member of a speakers' bureau or has made paid presentations on behalf of Smith & Nephew and ArthroSurface; serves as a paid consultant to or is an employee of Smith & Nephew; has received research or institutional support from Smith & Nephew, DJ Orthopaedics, Arthrex, and Össur; and has stock or stock options held in Omeros. Dr. Romeo or an immediate family member has received royalties from Arthrex; is a member of a speakers' bureau or has made paid presentations on behalf of Arthrex and DJ Orthopaedics; serves as a paid consultant to or is an employee of Arthrex; has received research or institutional support from Arthrex, Össur, and Smith & Nephew; has received nonincome support (such as equipment or services), commercially derived honoraria, or other non-research-related funding (such as paid travel) from Arthrex and DJ Orthopaedics; and serves as a board member, owner, officer, or committee member of the American Orthopaedic Society for Sports Medicine, American Shoulder and Elbow Surgeons, and Arthroscopy Association of North America. Neither of the following authors nor any immediate family member has received anything of value from or owns stock in a commercial company or institution related directly or indirectly to the subject of this article: Dr. Strauss and Dr. Lenart.

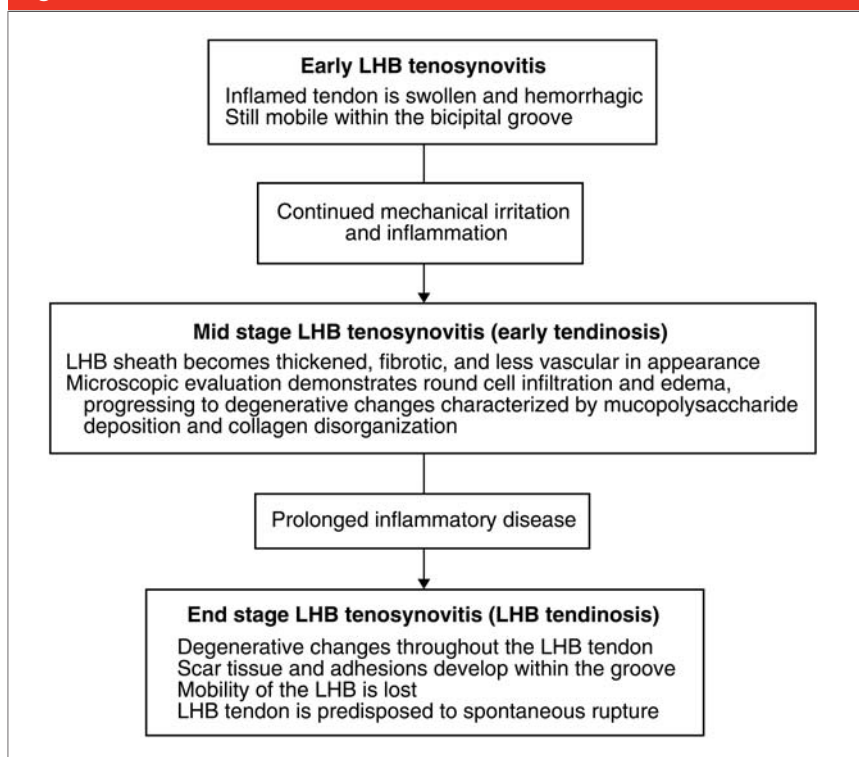
a relatively avascular zone in the region of the superior glenoid, which may contribute to the overall poor vascularity of the tendon.<sup>12</sup> Examination of the LHB within the groove characteristically shows vascularity on the superficial portion of the tendon, whereas the gliding undersurface has been noted to be avascular.

The biomechanical function of the LHB tendon is debated in the literature, and its role in glenohumeral kinematics remains controversial. The LHB has been described to function as a head depressor,<sup>2,13</sup> an anterior stabilizer,<sup>14-16</sup> and a posterior stabilizer.<sup>17</sup> It has even been said to have no role and has been described as a vestigial structure.<sup>18</sup> Cadaver biomechanical studies have demonstrated that the LHB tendon restricts glenohumeral translation in all directions but especially in the anterior and inferior directions; however, the manner in which the LHB tendon was loaded in these studies may not accurately represent its loading in vivo.<sup>13-16</sup> Recent electromyographic data presented in studies using controlled elbow motion suggest little biceps activity specific to the glenohumeral joint.<sup>4,6</sup> However, it is possible that, in vivo, tension on the LHB during active elbow motion may contribute to anterior shoulder stability.<sup>4,6</sup>

### Pathophysiology

Disorders of the LHB include a spectrum of pathologic conditions, from inflammatory tendinitis to degenerative tendinosis. This continuum of disease likely arises secondary to repetitive traction, friction, and glenohumeral rotation, with resultant pressure and shear forces occurring on the tendon at distinct, anatomically narrow sites within the long proximal tendon course.<sup>19</sup> The sheath of the biceps tendon is an extension of the synovial lining of the

**Figure 2**



Algorithm demonstrating the pathophysiology of long head of the biceps (LHB) tendinitis.

glenohumeral joint, and this sheath can become inflamed in conjunction with inflammatory processes that affect the rotator cuff tendons. In a prospective arthroscopic evaluation of 89 patients, Neviasser et al<sup>3</sup> correlated inflammatory changes in the LHB with rotator cuff tendinopathy. This association was found to become more pronounced with increasing severity of rotator cuff disease.

Isolated or primary bicipital tendinitis is seen less commonly in conjunction with LHB tendinopathy than with other shoulder pathology. However, it may occur secondary to direct or indirect trauma, underlying inflammatory disease, and in association with tendon instability. Such tendinitis progresses through a course from LHB tenosynovitis to LHB tendinosis, which is marked by specific gross and microscopic findings<sup>3,4,6</sup> (Figure 2).

### Clinical Evaluation and Diagnosis

#### History

Most patients report a progressive course of anterior shoulder pain and declining function as a result of chronic overuse, typically from repetitive overhead activities. It is difficult to differentiate the various causes of anterior shoulder pain, and a thorough history is important to elucidate activities and positions that are provocative (Table 1). Often, patients report pain in the anteromedial aspect of the shoulder, in the region of the bicipital groove. This pain may radiate down anteriorly to the biceps muscle belly.

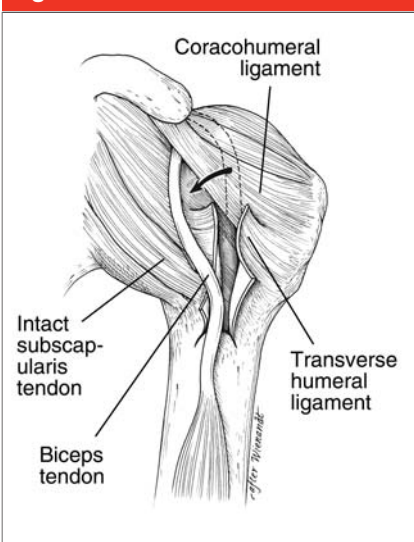
Patients with primary isolated biceps tendinitis tend to be younger and participate in overhead sports such as baseball, softball, and volley-

**Table 1**

**Differential Diagnosis of Anterior Shoulder Pain**

- Acromioclavicular joint pathology
- Impingement syndrome
- Rotator cuff tendinitis
- Rotator cuff tears
- Long head of the biceps tendinopathy
- Superior labrum anterior-posterior tears
- Subacromial bursitis
- Glenohumeral arthritis
- Adhesive capsulitis
- Glenohumeral instability
- Cervical spine pathology
- Humeral head osteonecrosis

**Figure 3**



Long head of the biceps (LHB) subluxation and dislocation may occur in patients with an intact rotator cuff secondary to injury to the coracohumeral ligament (CHL), superior glenohumeral ligament (SGHL), or transverse humeral ligament, which is composed in part of fibers from the CHL and SGHL. The arrow signifies medial dislocation of the LHB tendon (dashed line). (Redrawn with permission from Gambill ML, Mologne TS, Provencher MT: Dislocation of the long head of the biceps tendon with intact subscapularis and supraspinatus tendons. *J Shoulder Elbow Surg* 2006;15:e20-e22.)

ball.<sup>20</sup> Patients with symptoms related to biceps instability may report an acute event with ensuing clicking or popping in the anterior shoulder, and some patients may hear an audible snap with throwing motions.<sup>20,21</sup> LHB subluxation generally occurs in the setting of a partial- or full-thickness subscapularis tear, and the reported symptoms are usually concurrent with those found in rotator cuff disease.<sup>6</sup> However, LHB subluxation and dislocation have been reported in patients with an intact rotator cuff, as well<sup>22</sup> (Figure 3).

**Physical Examination**

The physical examination and clinical diagnosis of symptomatic biceps tendinopathy is often difficult because the findings are similar to those of other pathologic entities that affect the glenohumeral joint. One of the most common physical examination findings in patients with disorders of the LHB is point tenderness elicited by palpation of the tendon within the bicipital groove. In the subpectoral LHB tendon test, the examiner palpates the tendon just medial to the pectoralis major tendon insertion while the patient internally rotates the arm against resistance.<sup>23</sup> A greater amount of pain on the affected side during the test suggests that synovitis is localized to the bicipital groove. The unaffected, contralateral side should be tested for comparison. Gross deformity of the biceps muscle (ie, Popeye sign) is indicative of LHB tendon rupture.<sup>24</sup>

Several tests have been described to identify LHB tendinitis and associated pathology. However, no specific test or combination of tests has been reported to have a reliable positive predictive value. The Yergason test is positive in the presence of pain on palpation of the proximal biceps with resisted supination while the el-

bow is in 90° of flexion. The Speed test is positive with pain in the bicipital groove on resisted forward flexion of the arm with the forearm supinated, the elbow fully extended, and the humerus in 90° of forward flexion. Both tests are specific but not sensitive in detecting biceps tendinitis, rupture, and SLAP lesions.<sup>25</sup> Medial biceps instability can be elucidated with a painful click or tenderness to palpation on full abduction and external rotation of the arm. When dislocated, the biceps tendon can be rolled under the examiner’s fingers, eliciting increased tenderness.<sup>6</sup> The O’Brien active compression test may indicate a SLAP lesion; however, this test is also often positive in patients with LHB tendinitis or acromioclavicular arthrosis.

Selective injections may further aid in the diagnosis of shoulder pathology associated with LHB tendinitis.<sup>26</sup> A subacromial injection may relieve pain caused by impingement. When biceps pain persists, an injection into the bicipital groove may be given, as well, to help differentiate LHB tendinitis from other common causes of anterior shoulder pain. An intra-articular injection is also diagnostically and therapeutically useful, especially when a SLAP tear is suspected.

**Imaging Studies**

Imaging studies may be useful in the identification of biceps tendinitis and associated pathology. The typical plain radiographic views for shoulder evaluation (ie, AP, lateral, axial) should be obtained. Although these views are useful in diagnosing gross bony abnormalities and glenohumeral degeneration, they are seldom helpful in the diagnosis of LHB tendinitis and rupture. A visible outline of the tendon sheath on plain arthrography is suggestive of lack of inflammation; however, a negative



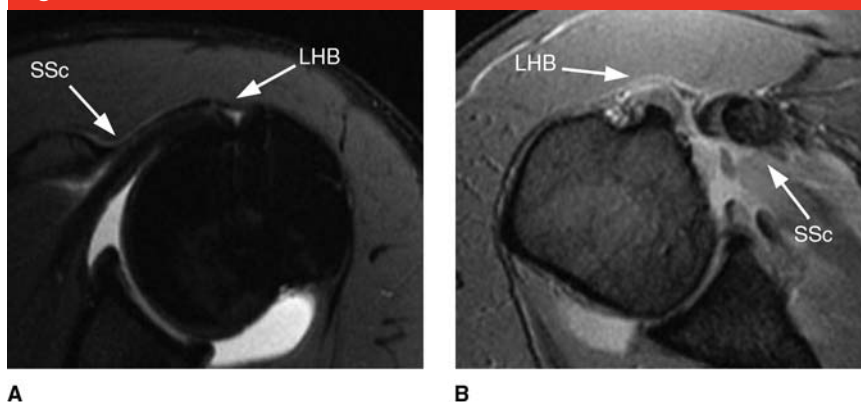
arthrogram is seen in >30% of cases with biceps pathology.<sup>27,28</sup>

MRI allows visualization of the biceps tendon, bicipital groove, bony osteophytes, and fluid. MRI is particularly helpful in identifying other associated pathology. However, most studies are neither precise nor accurate, and their quality is too varied to allow consistent identification of biceps tendinopathy. MRI has demonstrated poor concordance with arthroscopic findings in the detection of biceps pathology and poor to moderate sensitivity for inflammation, partial-thickness tear, and rupture.<sup>29</sup>

Magnetic resonance arthrography is sensitive and moderately specific for the diagnosis of biceps tendon pathology and aids in detection of associated pathology with tendinitis of the LHB, including rotator cuff tears and SLAP lesions.<sup>30,31</sup> On magnetic resonance arthrography, the LHB is normally surrounded by contrast fluid, with a shape similar to that of a kidney bean; neither finding should be mistaken as pathologic (Figure 4). Close inspection of advanced imaging studies (ie, MRI, magnetic resonance arthrography) is warranted in the axial plane and the sagittal oblique plane because LHB subluxation and dislocation are correlated with partial- and full-thickness subscapularis tendon tears.<sup>22</sup>

Ultrasound is cost-effective and accurate in the diagnosis of shoulder pathology, although this modality is highly operator-dependent. Ultrasound is highly accurate for detection of full-thickness tears of the rotator cuff as well as biceps dislocation, subluxation, and rupture; however, it is less accurate in detecting partial-thickness tears of the biceps tendon.<sup>32</sup> To date, the role of ultrasound in the diagnosis of biceps tendon inflammation has not been investigated.

**Figure 4**



**A**, T2-weighted axial magnetic resonance arthrogram demonstrating the long head of the biceps (LHB) tendon lying in the bicipital groove. **B**, T2-weighted axial magnetic resonance image demonstrating a torn subscapularis tendon (SSc) and medial dislocation of the LHB tendon.

### Nonsurgical Management

LHB tendinopathy is often initially managed nonsurgically, with techniques similar to those for the management of tendon disorders. This includes a period of rest and activity modification coupled with nonsteroidal anti-inflammatory drugs. Physical therapy is prescribed to correct the underlying scapular rhythm and to manage concomitant shoulder disorders. Should this initial treatment prove to be unsuccessful, corticosteroid injections may be attempted, first in the subacromial space and glenohumeral joint, to reduce the extent of inflammation that occurs secondary to the commonly associated shoulder pathology seen with biceps tendinitis. The sheath of the LHB is continuous with the synovium of the glenohumeral joint, and the effects of these injections often extend to the LHB, leading to a reduction in inflammation and an improvement in symptoms.<sup>26</sup> When the biceps remains symptomatic, the surgeon may inject the tendon sheath within the bicipital groove. The objective of a direct tendon sheath injection is to infiltrate the area in and around

the groove without injecting the tendon itself.<sup>26</sup> Although not well-documented, intratendinous corticosteroid injection may predispose the patient to tendon rupture.

Nonsurgical management of symptomatic biceps tendinopathy is the first-line treatment and is often successful. However, data are lacking in the literature to support the efficacy of this common approach.

### Surgical Management

The decision to perform surgical management of biceps pathology is dependent on the clinical presentation, results of provocative physical examination tests, presence of associated shoulder pathology, and failure of nonsurgical management. Indications for surgical management include partial-thickness tear of the LHB tendon of >25% to 50%, medial LHB subluxation, and LHB subluxation in the setting of a tear of the subscapularis tendon or biceps pulley/sling.<sup>4,33-36</sup> Relative indications for LHB surgery include type IV SLAP tear, symptomatic type II SLAP tear in an older patient (>50 years), failed SLAP repair, and chronic pain

**Table 2**  
**Studies Comparing Long Head of the Biceps Tenotomy and Tenodesis**

Study	Mean Age (yr)	No. of Shoulders		Mean Follow-up (mo)	Associated Shoulder Pathology	Popeye Sign
		Tenotomy	Tenodesis			
Osbaehr et al <sup>42</sup>	56	80	80	22	RCT impingement, AC arthrosis	No
Edwards et al <sup>43</sup>	53	13	48	45	Subscapularis tear	NR
Boileau et al <sup>41</sup>	68	39	33	35	RCT	Yes
Franceschi et al <sup>44</sup>	59	11	11	47	RCT	No
Paulos and Berg <sup>45</sup>	55	10	39	20	RCT and impingement	Yes

AC = acromioclavicular, LHB = long head of the biceps, NR = not reported, ROM = range of motion, RCT = rotator cuff tear, UCLA = University of California Los Angeles

attributable to LHB tendinitis that is refractory to nonsurgical management.<sup>1,4,37</sup> Other indications for surgical management include intraoperative findings of an inflamed “lipstick” biceps tendon and significant hypertrophy of the tendon (ie, hourglass LHB) during diagnostic arthroscopy in the setting of persistent symptoms attributable to biceps pathology.<sup>23,38</sup>

Optimal surgical management of LHB tendon pathology remains controversial.<sup>39</sup> The two most commonly performed procedures are biceps tenotomy and tenodesis. Biceps tenotomy can be performed with a relatively simple and reproducible technique that provides predictable pain relief and requires little postoperative rehabilitation. However, post-tenotomy cosmesis and fatigue discomfort are potential problems. The Popeye deformity has been reported to occur in 3% to 70% of cases following tenotomy.<sup>24,39,40</sup> However, this outcome is less likely

to be displeasing to older persons and those with obese arms. Fatigue cramping of the biceps muscle belly has also been reported; this occurs more commonly in younger persons, typically aged <40 years.<sup>24</sup> In a review of 54 patients with biceps tendinitis treated with arthroscopic tenotomy, Kelly et al<sup>24</sup> reported that 38% had fatigue discomfort in the biceps muscle after resisted elbow flexion activities. Thus, tenotomy is generally reserved for persons who are older, do not work as laborers, are unlikely to be displeased with cosmesis, and are unable or unwilling to comply with postoperative care following tenodesis.

The goal of biceps tenodesis is to maintain the length-tension relationship of the biceps muscle, which may prevent postoperative muscle atrophy and which helps to maintain the normal contour of the biceps muscle. Some authors believe that biceps tenodesis should be used in younger, active patients with LHB pathology.

Several clinical studies have been performed recently comparing the outcomes of tenotomy versus tenodesis (Table 2). Overall, despite a potentially higher incidence postoperatively of the Popeye sign, muscle cramping, and pain in the bicipital groove with tenotomy compared with tenodesis, these studies have not identified significant differences in functional scores or patient satisfaction between the two techniques. In a systematic review, Frost et al<sup>39</sup> found no significant differences in outcomes between biceps tenotomy and tenodesis. The authors concluded that tenotomy may be the procedure of choice because of its simplicity and the reduced need for postoperative rehabilitation.

Controversy persists regarding the optimal course of surgical management, and continued study is required. However, both tenotomy and tenodesis have been shown to be effective in the management of LHB tendinopathy.

Table 2 (continued)

## Studies Comparing Long Head of the Biceps Tenotomy and Tenodesis

Difference Between Techniques	Comments
No	No difference with respect to cosmesis, extent of postoperative pain, or muscle spasm
No	Tenodesis or tenotomy of the LHB with subscapularis repair was associated with improved subjective and objective results
Higher incidence of Popeye sign with tenotomy vs tenodesis (62% vs 3%, respectively), postoperative muscle cramping (21% vs 9%, respectively), and pain in the bicipital groove (46% vs 30%, respectively)	No difference in Constant score, patient satisfaction, or shoulder ROM
No	All patients had good to excellent results on UCLA score
Higher incidence of Popeye sign (80% tenotomy vs 5% tenodesis)	No difference in UCLA score or patient satisfaction

AC = acromioclavicular, LHB = long head of the biceps, NR = not reported, ROM = range of motion, RCT = rotator cuff tear, UCLA = University of California Los Angeles

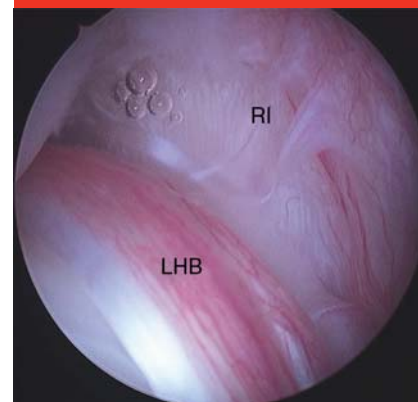
### Arthroscopic Débridement and Biceps Tenotomy

Arthroscopic tenotomy can be performed with the patient in the beach-chair or the lateral decubitus position, depending on the concomitant procedures required. A standard posterior portal is established and is used for diagnostic arthroscopy, after which an anterior portal is created in the rotator interval under direct visualization. The LHB is evaluated “dry,” with no pump pressure, because the intra-articular pressure of the infusion fluid may compress the peritendinous vessels, causing the inflamed synovium to appear washed out.<sup>23</sup> A lipstick biceps has been described as an inflamed LHB within the bicipital groove. This is visualized as a high amount of inflammation on the tendon surface when the LHB is retracted into the joint<sup>23</sup> (Figure 5). An hourglass LHB tendon can be visualized arthroscopically.<sup>38</sup> In this finding, hypertrophy of the biceps within the groove is believed

to cause mechanical symptoms.

It is critical that the intertubercular groove portion of the LHB be brought into the joint because the pathologic areas are commonly located in this portion. In addition, the surgeon should evaluate the stability of the LHB within the biceps pulley by attempting to sublaxate the tendon out of the sling using the probe.<sup>46,47</sup> Although the arthroscopic active compression test is typically used in the diagnosis of unstable SLAP lesions, it can also be used to identify medial and inferior LHB subluxation.<sup>47</sup> In the case of LHB instability, the tendon is noted to displace medially and inferiorly during internal rotation, becoming entrapped within the glenohumeral joint. On external rotation of the arm, the entrapment is relieved, and the tendon returns to its normal position. Following arthroscopic confirmation of LHB instability, the integrity of the subscapularis and supraspinatus tendons as well as of

Figure 5



Dry arthroscopic image of a left shoulder demonstrating hyperemic tenosynovium (ie, lipstick biceps). LHB = long head of the biceps, RI = rotator interval

the components of the biceps pulley/sling (ie, CHL, SGHL) is carefully assessed to aid in determining the surgical approach.<sup>8,22,47</sup>

Some surgeons may elect to débride the LHB tendon with a shaver in the patient with arthroscopic evidence of <30% to 50% of intra-articular LHB fraying without instability. When arthroscopic tenotomy is indicated, an arthroscopic basket is used to release the LHB as close as possible to the superior labrum, thereby ensuring that the confluence of the superior labral ring is maintained. After release, the LHB tendon should easily retract toward the bicipital groove. In some instances the LHB is hypertrophic and is unable to retract, leaving a portion of the tendon intra-articular. This may serve as a potential source of postoperative pain. In these cases, the end of the tendon must be débrided until it can retract untethered into the bicipital groove.<sup>38</sup> In an effort to decrease the incidence of Popeye deformity following tenotomy, Bradbury et al<sup>48</sup> suggest releasing the LHB along with a portion of the superior labrum. This technique produces a T-shaped structure at the proximal end of the

LHB, leading to entrapment at the entrance to the bicipital groove.

Gill et al<sup>40</sup> explored biceps tenotomy as an option for the management of primary LHB pathology. After arthroscopic tenotomy, patients reported high rates of pain-free recovery, return to work, and return to sports, with a mean American Shoulder and Elbow Surgeons (ASES) score of 81.8. In a similar study of 40 patients with biceps tendinitis with or without associated shoulder pathology, Kelly et al<sup>24</sup> reported that patient satisfaction was high following arthroscopic tenotomy (average ASES score, 77.6). Although improvement with respect to pain was high, 70% of the patients in this study displayed the classic Popeye sign at rest or during active elbow flexion, and 38% reported fatigue discomfort after resisted elbow flexion.

### Long Head of the Biceps Tenodesis

Tenodesis is the preferred technique for managing pathology of the LHB in younger persons, athletes and laborers, and those who wish to avoid cosmetic deformity. Tenodesis allows for preservation of the length-tension relationship of the biceps muscle, which may prevent postoperative muscle atrophy and fatigue cramping, and which helps to maintain the normal contour of the biceps muscle.

Recent controversy surrounding biceps tenodesis pertains to the location and method of fixation. Biceps tenodesis can be performed proximally, with the tendon maintained within the bicipital groove,<sup>41,49,50</sup> or distally, with the tendon removed from the groove.<sup>9,35,36,50-53</sup> Advocates of distal fixation report that removing the LHB from the bicipital groove and excising the proximal portion of the tendon limits the potential for postoperative pain secondary to residual tenosynovitis

within the biceps sheath.<sup>54,55</sup> Sanders et al<sup>56</sup> reported a 12% revision rate with proximal tenodesis techniques in which the LHB remained within the bicipital groove, compared with a 2.7% rate when the LHB was fixed distally, outside the groove.

Proximal fixation can be performed with an all-arthroscopic technique within the glenohumeral joint or subdeltoid space to the surrounding intact rotator cuff<sup>57</sup> or to the conjoint tendon,<sup>58</sup> or just proximal within the bicipital groove.<sup>9,24,35,36,50,51,53</sup> In a review of 43 patients treated with arthroscopic proximal tenodesis using interference screw fixation, Boileau and Neyton<sup>52</sup> found the power of the biceps to be 90% that of the unaffected contralateral side. Elkousy et al<sup>57</sup> reported preliminary results in 11 patients following arthroscopic biceps tenodesis using a percutaneous intra-articular trans-tendon technique. All 11 patients had biceps strength equal to that of the contralateral side, and all were satisfied with their postoperative outcome.

Distal fixation may involve the use of bone tunnels,<sup>55</sup> keyholes,<sup>33</sup> suture to a bed of decorticated bicipital groove, interference screws,<sup>23,33,36,50,51,53,55,58-60</sup> and suture anchors.<sup>24,33,55,59,60</sup> Several biomechanical studies have shown the interference screw technique to have the highest ultimate load to failure and the least amount of displacement on cyclic loading compared with suture anchor and other methods of fixation.<sup>33,55,60-62</sup>

### Arthroscopic Biceps Tenodesis

Arthroscopic biceps tenodesis can be performed in either the lateral decubitus or beach-chair position. Prior to tenotomy, the tendon undergoes intra-articular transfixion with a spinal needle at its entrance into the bicipital groove (Figure 6). Following

tenotomy, the arthroscope, which is placed in the posterior portal, and the anteromedial working cannula are redirected into the subacromial space. The arthroscope is then inserted into an anterolateral portal for viewing. A probe is used to identify the location of the bicipital groove, which typically lies just medial to the lateral aspect of the greater tuberosity.<sup>58</sup>

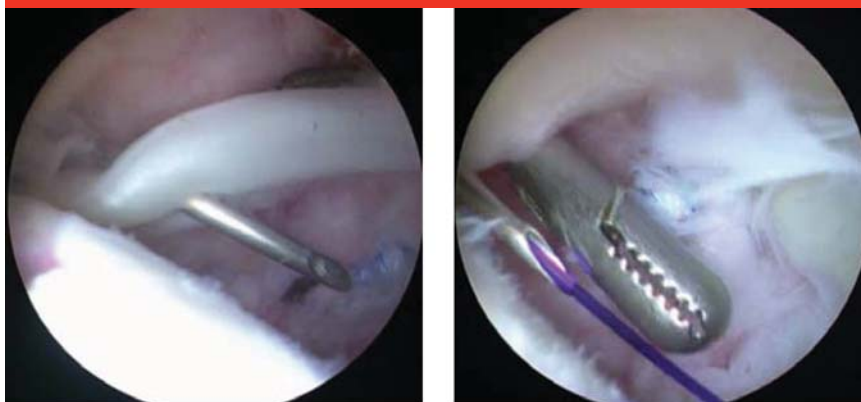The bicipital groove is opened using a cautery device, exposing the LHB. The LHB is then grasped while the spinal needle is removed, which allows removal of the tendon from the groove (Figure 7). Using a shaver or cautery device, the bicipital groove is cleared of tissue in preparation for drilling of the humeral socket. Approximately 1 cm distal to the most superior aspect of the groove, a guidewire is drilled perpendicular to the humerus and parallel to the lateral border of the acromion. Using a 7- or 8-mm cannulated reamer, the guidewire is then overdrilled to a depth of 25 mm (Figure 8). An arthroscopic grasper is used to apply tension to the LHB, and the LHB tendon is inserted into the humeral socket using a tendon fork. A guidewire for the interference screw is inserted through the tendon fork, maintaining appropriate tension on the LHB. The tendon is then fixed within the socket using a 9- × 25-mm interference screw with the patient's elbow in 45° to 90° of flexion (Figure 9). Tension in the tenodesed LHB is assessed using the probe.<sup>58</sup>

### Subpectoral Open Biceps Tenodesis

Several open techniques have been described for both proximal and distal LHB tenodesis. However, we prefer to use a mini-open subpectoral approach. Following release of the LHB tendon, the head of the beach-chair



Figure 6

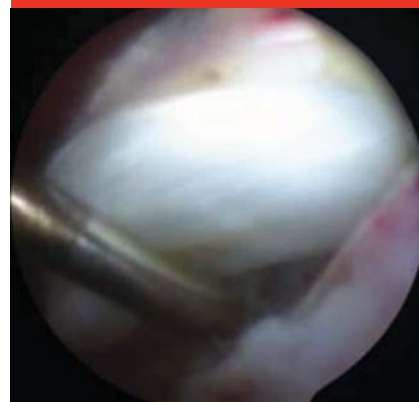

A

B

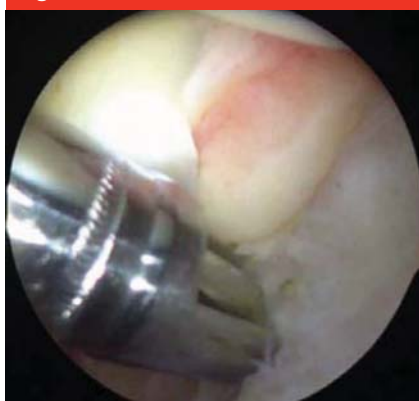Prior to tenotomy, the long head of the biceps tendon is pierced with a spinal needle (A) and tagged with a polypropylene suture (B).

Figure 7



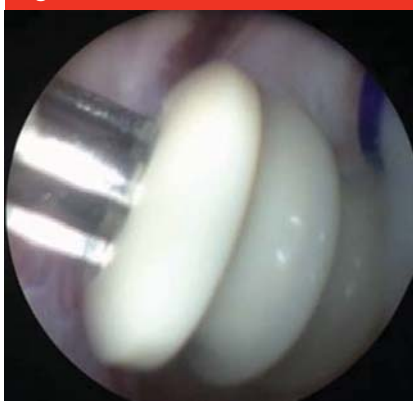Arthroscopic image demonstrating the long head of the biceps tendon being delivered from the bicipital groove.

Figure 8



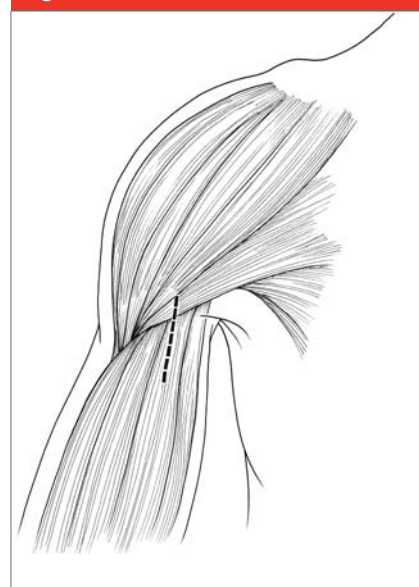
Arthroscopic humeral socket drilling using an 8-mm cannulated reamer over an inserted guidewire.

Figure 9



Arthroscopic long head of the biceps tenodesis fixation using a 9 x 25-mm interference screw.

Figure 10



Open subpectoralis biceps tenodesis incision (dashed line). The incision is approximately 3 cm in length, with 1 cm superior to the inferior border of the pectoralis major tendon and 2 cm inferior to that structure.

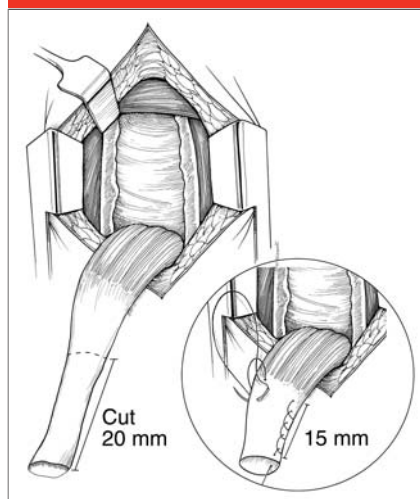
position. The arm is abducted and internally rotated so that the inferior border of the pectoralis tendon is palpable. An incision is made along the axillary fold or along the medial aspect of the arm, beginning 1 cm superior to the inferior border of the pectoralis tendon and continuing 2 cm distally (Figure 10). The dissection is carried down directly over the humerus, taking care to avoid excessive medial exposure to prevent injury to the neurovascular structures. The inferior border of the pectoralis major tendon is identified, and the

fascia overlying the coracobrachialis and biceps muscles is incised from proximal to distal. Digital palpation helps to identify the LHB sitting in the groove just medial to the pectoralis major tendon insertion.

Once the LHB is mobilized, it is delivered out of the wound. A clamp is placed on the proximal end of the tendon, and a Krakow stitch with a No. 2 permanent braided suture is passed from 15 mm proximal to the musculotendinous junction. The approximately 20 mm of remaining tendon proximal to the Krakow

stitch is excised to maintain the correct length-tension relationship for the tenodesis (Figure 11). A periosteal elevator is used to prepare the humeral bone approximately 1 cm proximal to the inferior border of

**Figure 11**

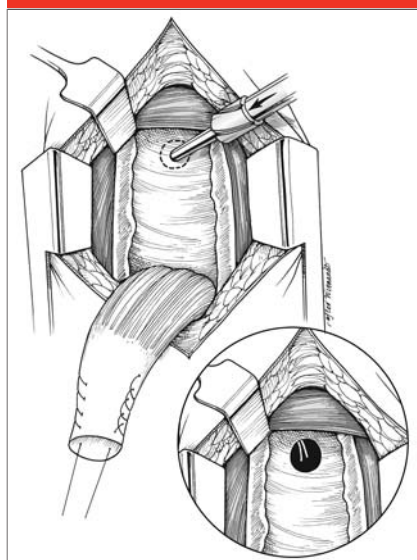


Long head of the biceps tendon preparation. The proximal 20 mm is excised, and a Krackow stitch is made through the proximal tendon end to the musculotendinous junction (inset).

the pectoralis major tendon.

Several fixation techniques have been described for use with open subpectoral biceps tenodesis. We prefer to use interference screw fixation, as described by Mazzocca et al.<sup>23</sup> The intent is to position the musculotendinous junction at its normal resting position, just beneath the inferior border of the pectoralis major tendon, to maintain an anatomic length-tension relationship. A guidewire is positioned in the center of the bicipital groove 1 cm proximal to the inferior border of the pectoralis major tendon. Using an 8-mm cannulated reamer, the guidewire is over-reamed to a depth of 15 mm. One suture is passed through the tenodesis screwdriver and screw (eg, 8- × 12-mm polyetheretherketone tenodesis screw; Bio-Tenodesis, Arthrex, Naples, FL), and the other limb is left out (Figure 12). The driver is placed into the bone tunnel, fully seating the tendon within the tunnel, and the screw is advanced until it is flush with the surrounding bone. The

**Figure 12**



Biceps tenodesis site preparation. A guidewire is positioned in the bicipital groove 1 cm proximal to the inferior border of the pectoralis major tendon and over-reamed with an 8-mm reamer (inset).

suture limb through the screw and the limb next to the tendon are tied together. The wound is irrigated and closed with No. 2-0 absorbable, monofilament sutures and Dermabond (Ethicon, Somerville, NJ) to reduce contamination from the axilla.

### Postoperative Protocol

Postoperatively, the patient is placed in a sling. For isolated biceps tenodesis the sling is discontinued at 3 to 4 weeks, but the length of immobilization and the rehabilitation protocol are dictated by concomitant procedures. The patient progresses to full glenohumeral active and passive range of motion during the first 6 weeks. Elbow range of motion and grip strengthening may commence during this initial postoperative period, but patients are restricted from active elbow flexion and supination exercises until the 6-week follow-up

visit. Patients may resume light work at 3 to 4 weeks depending on their occupation. Depending on their progress with physical therapy, patients are typically able to return to unrestricted activity at 3 to 4 months postoperatively.

### Complications

Nho et al<sup>63</sup> recently reported on the complications after open subpectoral biceps tenodesis over a 3-year period. Seven of 353 patients presented with postoperative complications, for an incidence of 0.7% per year. Two patients had persistent bicipital pain, and two had failed fixation with an associated Popeye deformity (0.2% for each). One patient each presented with the following complications (0.1%): wound infection, temporary musculocutaneous neuropathy, complex regional pain syndrome, and proximal humerus fracture.

### Summary

LHB tendinopathy is a common source of shoulder pain, and it often occurs in combination with other shoulder pathology. Once the diagnosis of LHB tendinitis has been established, patients are treated nonsurgically with rest, ice, nonsteroidal anti-inflammatory drugs, activity modification, and physical therapy. Selective cortisone injections play a role in nonsurgical management, serving both diagnostic and therapeutic purposes.

Patients with symptoms refractory to nonsurgical management are indicated for biceps tenotomy or tenodesis. To date, the literature does not provide evidence to support one technique over the other, and there are advantages to each procedure. The authors' preferred method is open subpectoral biceps tenodesis

with interference screw fixation, which provides the strongest fixation construct with a technique that removes the intertubercular portion of the LHB tendon and provides fixation at the resting position of the biceps tendon.

## References

*Evidence-based Medicine:* Levels of evidence are described in the table of contents. In this article, references 25, 29-32, and 37 are level I studies. References 2 and 44 are level II studies. References 28, 39, 41, and 42 are level III studies. References 3, 8, 24, 38, 40, 43, 46, 49, 57, 58, and 60 are level IV studies.

Citation numbers printed in **bold type** indicate references published within the past 5 years.

1. Ahrens PM, Boileau P: The long head of biceps and associated tendinopathy. *J Bone Joint Surg Br* 2007;89(8):1001-1009.
2. Post M, Benca P: Primary tendinitis of the long head of the biceps. *Clin Orthop Relat Res* 1989;(246):117-125.
3. Neviaser TJ, Neviaser RJ, Neviaser JS, Neviaser JS: The four-in-one arthroplasty for the painful arc syndrome. *Clin Orthop Relat Res* 1982;(163):107-112.
4. Sethi N, Wright R, Yamaguchi K: Disorders of the long head of the biceps tendon. *J Shoulder Elbow Surg* 1999; 8(6):644-654.
5. Tuoheti Y, Itoi E, Yamamoto N, et al: Contact area, contact pressure, and pressure patterns of the tendon-bone interface after rotator cuff repair. *Am J Sports Med* 2005;33(12):1869-1874.
6. Yamaguchi K: *Disorders of the Biceps Tendon*. Philadelphia, PA, Lippincott Williams and Wilkins, 1999.
7. Gleason PD, Beall DP, Sanders TG, et al: The transverse humeral ligament: A separate anatomical structure or a continuation of the osseous attachment of the rotator cuff? *Am J Sports Med* 2006;34(1):72-77.
8. Walch G, Nove-Josserand L, Levigne C, Renaud E: Tears of the supraspinatus tendon associated with "hidden" lesions of the rotator interval. *J Shoulder Elbow Surg* 1994;3(6):353-360.
9. Romeo AA, Mazzocca AD, Tauro JC: Arthroscopic biceps tenodesis. *Arthroscopy* 2004;20(2):206-213.
10. Alpantaki K, McLaughlin D, Karageorgos D, Hadjipavlou A, Kontakis G: Sympathetic and sensory neural elements in the tendon of the long head of the biceps. *J Bone Joint Surg Am* 2005; 87(7):1580-1583.
11. Rathbun JB, Macnab I: The microvascular pattern of the rotator cuff. *J Bone Joint Surg Br* 1970;52(3):540-553.
12. Abrassart S, Stern R, Hoffmeyer P: Arterial supply of the glenoid: An anatomic study. *J Shoulder Elbow Surg* 2006;15(2):232-238.
13. McGough RL, Debski RE, Taskiran E, Fu FH, Woo SL: Mechanical properties of the long head of the biceps tendon. *Knee Surg Sports Traumatol Arthrosc* 1996;3(4):226-229.
14. Sakurai G, Ozaki J, Tomita Y, Nishimoto K, Tamai S: Electromyographic analysis of shoulder joint function of the biceps brachii muscle during isometric contraction. *Clin Orthop Relat Res* 1998;(354):123-131.
15. Malicky DM, Soslowky LJ, Blasler RB, Shyr Y: Anterior glenohumeral stabilization factors: Progressive effects in a biomechanical model. *J Orthop Res* 1996;14(2):282-288.
16. Nidecker A, Gückel C, von Hochstetter A: Imaging the long head of biceps tendon: A pictorial essay emphasizing magnetic resonance. *Eur J Radiol* 1997; 25(3):177-187.
17. McMahan PJ, Burkart A, Musahl V, Debski RE: Glenohumeral translations are increased after a type II superior labrum anterior-posterior lesion: A cadaveric study of severity of passive stabilizer injury. *J Shoulder Elbow Surg* 2004;13(1):39-44.
18. Lippmann R: Bicipital tenosynovitis. *N Y State J Med* 1944;44:2235-2240.
19. Refior HJ, Sowa D: Long tendon of the biceps brachii: Sites of predilection for degenerative lesions. *J Shoulder Elbow Surg* 1995;4(6):436-440.
20. Patton WC, McCluskey GM III: Biceps tendinitis and subluxation. *Clin Sports Med* 2001;20(3):505-529.
21. Curtis AS, Snyder SJ: Evaluation and treatment of biceps tendon pathology. *Orthop Clin North Am* 1993;24(1):33-43.
22. Gambill ML, Mologne TS, Provencher MT: Dislocation of the long head of the biceps tendon with intact subscapularis and supraspinatus tendons. *J Shoulder Elbow Surg* 2006;15(6):e20-e22.
23. Mazzocca AD, Rios CG, Romeo AA, Arciero RA: Subpectoral biceps tenodesis with interference screw fixation. *Arthroscopy* 2005;21(7):896.
24. Kelly AM, Drakos MC, Fealy S, Taylor SA, O'Brien SJ: Arthroscopic release of the long head of the biceps tendon: Functional outcome and clinical results. *Am J Sports Med* 2005;33(2):208-213.
25. Holtby R, Razmjou H: Accuracy of the Speed's and Yergason's tests in detecting biceps pathology and SLAP lesions: Comparison with arthroscopic findings. *Arthroscopy* 2004;20(3):231-236.
26. Tallia AF, Cardone DA: Diagnostic and therapeutic injection of the shoulder region. *Am Fam Physician* 2003;67(6): 1271-1278.
27. Ahovuo J: Radiographic anatomy of the intertubercular groove of the humerus. *Eur J Radiol* 1985;5(2):83-86.
28. Ahovuo J, Paavolainen P, Slätis P: Radiographic diagnosis of biceps tendinitis. *Acta Orthop Scand* 1985; 56(1):75-78.
29. Mohtadi NG, Vellet AD, Clark ML, et al: A prospective, double-blind comparison of magnetic resonance imaging and arthroscopy in the evaluation of patients presenting with shoulder pain. *J Shoulder Elbow Surg* 2004;13(3):258-265.
30. Zanetti M, Weishaupt D, Gerber C, Hodler J: Tendinopathy and rupture of the tendon of the long head of the biceps brachii muscle: Evaluation with MR arthrography. *AJR Am J Roentgenol* 1998;170(6):1557-1561.
31. Pfirrmann CW, Zanetti M, Weishaupt D, Gerber C, Hodler J: Subscapularis tendon tears: Detection and grading at MR arthrography. *Radiology* 1999; 213(3):709-714.
32. Teefey SA, Hasan SA, Middleton WD, Patel M, Wright RW, Yamaguchi K: Ultrasonography of the rotator cuff: A comparison of ultrasonographic and arthroscopic findings in one hundred consecutive cases. *J Bone Joint Surg Am* 2000;82(4):498-504.
33. Ozalay M, Akpinar S, Karaeminogullari O, et al: Mechanical strength of four different biceps tenodesis techniques. *Arthroscopy* 2005;21(8):992-998.
34. Barber FA, Byrd JW, Wolf EM, Burkhart SS: How would you treat the partially torn biceps tendon? *Arthroscopy* 2001; 17(6):636-639.
35. Klepps S, Hazrati Y, Flatow E: Arthroscopic biceps tenodesis. *Arthroscopy* 2002;18(9):1040-1045.
36. Lo IK, Burkhart SS: Arthroscopic biceps tenodesis using a bioabsorbable interference screw. *Arthroscopy* 2004; 20(1):85-95.



37. Franceschi F, Longo UG, Ruzzini L, Rizzello G, Maffulli N, Denaro V: No advantages in repairing a type II superior labrum anterior and posterior (SLAP) lesion when associated with rotator cuff repair in patients over age 50: A randomized controlled trial. *Am J Sports Med* 2008;36(2):247-253.

38. Boileau P, Ahrens PM, Hatzidakis AM: Entrapment of the long head of the biceps tendon: The hourglass biceps. A cause of pain and locking of the shoulder. *J Shoulder Elbow Surg* 2004; 13(3):249-257.

39. Frost A, Zafar MS, Maffulli N: Tenotomy versus tenodesis in the management of pathologic lesions of the tendon of the long head of the biceps brachii. *Am J Sports Med* 2009;37(4): 828-833.

40. Gill TJ, McIrvine E, Mair SD, Hawkins RJ: Results of biceps tenotomy for treatment of pathology of the long head of the biceps brachii. *J Shoulder Elbow Surg* 2001;10(3):247-249.

41. Boileau P, Baqué F, Valerio L, Ahrens P, Chuinard C, Trojani C: Isolated arthroscopic biceps tenotomy or tenodesis improves symptoms in patients with massive irreparable rotator cuff tears. *J Bone Joint Surg Am* 2007;89(4): 747-757.

42. Osbahr DC, Diamond AB, Speer KP: The cosmetic appearance of the biceps muscle after long-head tenotomy versus tenodesis. *Arthroscopy* 2002;18(5):483-487.

43. Edwards TB, Walch G, Sirveaux F, et al: Repair of tears of the subscapularis: Surgical technique. *J Bone Joint Surg Am* 2006;88(suppl 1 pt 1):1-10.

44. Franceschi F, Longo UG, Ruzzini L, Papalia R, Rizzello G, Denaro V: To detach the long head of the biceps tendon after tenodesis or not: Outcome analysis at the 4-year follow-up of two different techniques. *Int Orthop* 2007; 31(4):537-545.

45. Paulos LE, Berg T: A novel approach to biceps tenodesis. *Operative Techniques in Sports Medicine* 2007;15(1):27-34.

46. Bennett WF: Arthroscopic repair of anterosuperior (supraspinatus/subscapularis) rotator cuff tears: A prospective cohort with 2- to 4-year follow-up. Classification of biceps subluxation/instability. *Arthroscopy* 2003;19(1):21-33.

47. Verma NN, Drakos M, O'Brien SJ: The arthroscopic active compression test. *Arthroscopy* 2005;21(5):634.

48. Bradbury T, Dunn WR, Kuhn JE: Preventing the popeye deformity after release of the long head of the biceps tendon: An alternative technique and biomechanical evaluation. *Arthroscopy* 2008;24(10):1099-1102.

49. Becker DA, Cofield RH: Tenodesis of the long head of the biceps brachii for chronic bicipital tendinitis: Long-term results. *J Bone Joint Surg Am* 1989; 71(3):376-381.

50. Richards DP, Burkhart SS: Arthroscopic-assisted biceps tenodesis for ruptures of the long head of biceps brachii: The cobra procedure. *Arthroscopy* 2004; 20(suppl 2):201-207.

51. Kim SH, Yoo JC: Arthroscopic biceps tenodesis using interference screw: End-tunnel technique. *Arthroscopy* 2005; 21(11):1405.

52. Boileau P, Neyton L: Arthroscopic tenodesis for lesions of the long head of the biceps. *Oper Orthop Traumatol* 2005;17(6):601-623.

53. Gartsman GM, Hammerman SM: Arthroscopic biceps tenodesis: Operative technique. *Arthroscopy* 2000;16(5):550-552.

54. Friedman DJ, Dunn JC, Higgins LD, Warner JJ: Proximal biceps tendon: Injuries and management. *Sports Med Arthrosc* 2008;16(3):162-169.

55. Mazzocca AD, Bicos J, Santangelo S, Romeo AA, Arciero RA: The biomechanical evaluation of four fixation techniques for proximal biceps tenodesis. *Arthroscopy* 2005;21(11): 1296-1306.

56. Sanders BS, Warner JJ, Pennington S, Lavery KP: Biceps tendon tenodesis: Success with proximal versus distal fixation. *74th Annual Meeting Proceedings. Rosemont, IL, American Academy of Orthopaedic Surgeons, 2007, p 572.*

57. Elkousy HA, Fluhme DJ, O'Connor DP, Rodosky MW: Arthroscopic biceps tenodesis using the percutaneous, intra-articular trans-tendon technique: Preliminary results. *Orthopedics* 2005; 28(11):1316-1319.

58. Boileau P, Krishnan SG, Coste JS, Walch G: Arthroscopic biceps tenodesis: A new technique using bioabsorbable interference screw fixation. *Arthroscopy* 2002;18(9):1002-1012.

59. Richards DP, Burkhart SS: A biomechanical analysis of two biceps tenodesis fixation techniques. *Arthroscopy* 2005;21(7):861-866.

60. Kilicoglu O, Koyuncu O, Demirhan M, et al: Time-dependent changes in failure loads of 3 biceps tenodesis techniques: In vivo study in a sheep model. *Am J Sports Med* 2005;33(10):1536-1544.

61. Golish SR, Caldwell PE III, Miller MD, et al: Interference screw versus suture anchor fixation for subpectoral tenodesis of the proximal biceps tendon: A cadaveric study. *Arthroscopy* 2008; 24(10):1103-1108.

62. Kusma M, Dienst M, Eckert J, Steimer O, Kohn D: Tenodesis of the long head of biceps brachii: Cyclic testing of five methods of fixation in a porcine model. *J Shoulder Elbow Surg* 2008;17(6):967-973.

63. Nho SJ, Reiff SN, Verma NN, Slabaugh MA, Mazzocca AD, Romeo AA: Complications associated with subpectoral biceps tenodesis: Low rates of incidence following surgery. *J Shoulder Elbow Surg* 2010;19(5):764-768.